

Surgical Treatment of Rheumatoid Arthritis

Michael Goldberger MD
Tricounty Orthopaedics
Morristown , NJ

What makes you so special

- very nice patients
- chronic disease
- realistic expectations
- long relationship

Philosophy

Is surgery nonoperative failure?

- balance between living with the pain, loss of function and improved function/lifestyle
- longevity of the surgery- fusion vs mechanical device
- "Don't get old"
- perception of baby boomers



What makes you so special part 2

- Medication
 - steroids
 - nsoids
- Vasculitis
- Osteopenia
- Higher infection rates

Common denominator of arthritis

- loss of cartilage
- pain
- *loss of function

Types of Joint Surgery

- fusion
- resection arthroplasty
- replacement arthroplasty

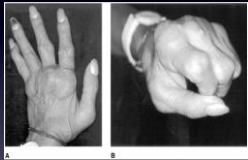
Tendon Surgery

- tenosynovectomy
- tendon transfer

Where do you start?

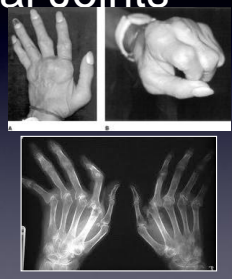- polyarticular
- worse joints first
- upper extremity before lower extremity
- Hip before knee
- hand/wrist before shoulder

The Hand/Wrist



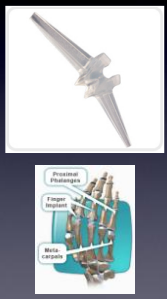Metacarpal Phalangeal Joints

- Inflammation(synovitis)
) destroys ligaments-
>destroys cartilage-
>joints out of sockets
(subluxation)
- pain
- moved to
nonfunctional position



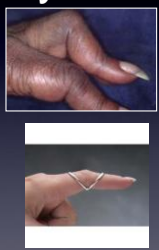
MCP Joint Treatment

- Early synovectomy
- short term
improvement
- Silicone interposition
arthroplasty



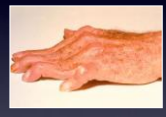Boutonniere deformity

- flexion deformity at
PIP joint and
extension DIP
- inflammation destroys
support structure
- splint finger
- reconstruction
ligaments
- fusion



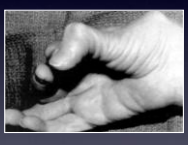Swan-neck deformity

- hyperextension at PIP
flexion at DIP
- inflammation destroys
ligaments
- splints
- fusion



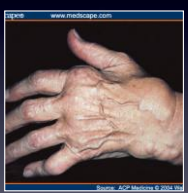Thumb

- Flexor /Extensor
tendon ruptures
- Boutonniere/ swan
neck deformities
- MCP/CMC arthritis



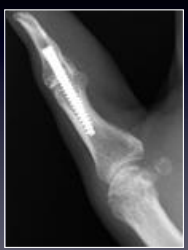Thumb tendon repairs

- dorsal synovitis->EPL
rupture: primary repair
or Extensor Indicis
transfer
- FPL- loss of flexion-
graft or transfer FDL



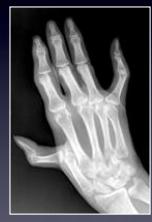Interphalangeal Joint

- if MCP and CMC joint spared --> Fusion
- increased pinch ability



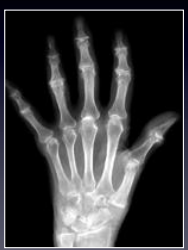Metacarpal-phalangeal joint

- silicone implants and tendon rerouting
- *Arthrodesis if IP and CMC spared



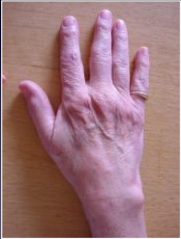Carpometacarpal

- Resection arthroplasty
- if isolated -fusion
- replacement



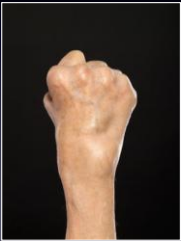
Wrist

- 66% wrist involvement
- Caput ulnae syndrome
- Radial side erosion and collapse
- Tendon ruptures



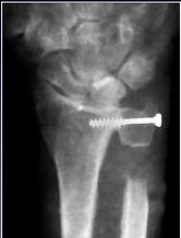Wrist treatment

- Synovectomy >6 months symptoms
- Tendon transfer
- Carpal tunnel release



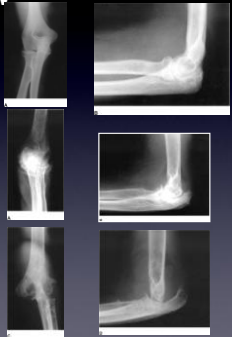Distal Radioulnar Joint

- Motion sparing
 - Dislocation of ulna → excise distal ulna (Darrach)
 - Sauve-Kapandji-Fusion of DRUJ and excision distal ulna
 - Partial wrist fusion-disease include carpal bones
- Fusions
- Wrist replacement
 - Wrist fusion-?function



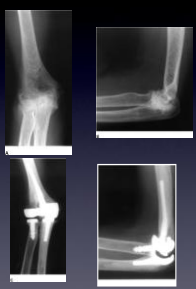Elbow

- 20- 50%
- synovitis
- Dislocation of radial head/ instability
- erosion of articular cartilage
- Flexion contracture
- nerve compression



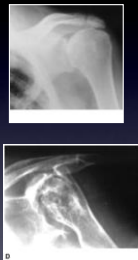
Elbow treatment

- Early synovectomy
- Dislocated Radial Head - excision (poor results with silicone & metal)
- Advance Arthritis - Prosthetic replacement



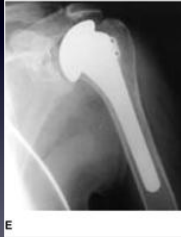
Shoulder

- Long standing RA 91%
- Pain and loss of ROM
- destruction of rotator cuff



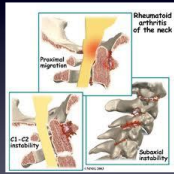
Shoulder RA Treatment

- Intra-articular steroid/ PT
- 3 months before LE Surgery
- Hand and wrist first
- Hemiarthroplasty vs Total Shoulder Arthroplasty



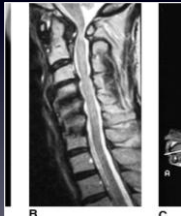Cervical spine

- occurs early(3rd most common)
- **Asymptomatic**(20-60%)
- Clunking sensation during flexion
- sleep apnea
- Myelopathy-extremity weakness/ loss of fine coordination



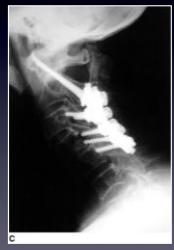Atlantoaxial subluxation

- 49%
- C1 C2
- decrease space available for spinal cord



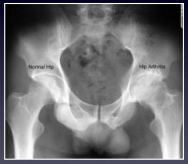Treatment

- soft collar
- decompression
- fusion



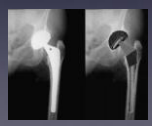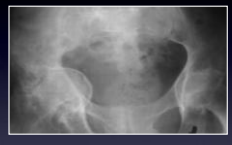Rheumatoid Arthritis of the Hip

- 15-28% RA, 10-38% JRA
- greater risk of hip fracture
- pain -> groin
- *bilateral



Hip RA Treatment

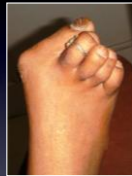- hip before knee
- Protrusio
- Total Hip Replacement



The Foot & Ankle

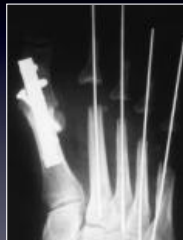Forefoot

- synovitis->destroy ligaments
- dorsal dislocation of MTP joints
- large plantar callus
- Bunion -hallux valgus



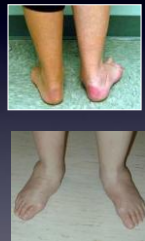
Forefoot treatment

- synovectomy
- Hallux - Arthrodesis
- Lesser toes-resection arthroplasty



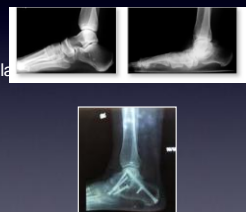Rheumatoid arthritis of the Hind foot

- Isolated Talo-navicular joint arthritis
- Flatfoot-pes planovalgus
- posterior tibial tenosynovitis



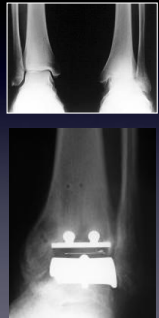
Rheumatoid arthritis of the Hind foot

- isolated talonavicular arthrodesis
- triple arthrodesis



Ankle arthritis

- relatively uncommon- 10%
- Fusion-gold standard
- Replacement Indications
 - Age>55
 - peritalar arthritis
 - good circulation



How to choose your doctor

- Does volume make a difference
- How much?
- Fellowship trained surgeons
- Need to have appreciation of RA
- Why: Manage unexpected

Thank you
